

Delayed Maturation of Interstitial Cells of Cajal in Meconium Obstruction

By Soo-Young Yoo, Soon-Hee Jung, Minseob Eom, Il-ho Kim, and Airi Han
Wonju, Korea

Background/Purpose: The etiology of meconium obstruction without cystic fibrosis is unclear. Interstitial cells of Cajal (ICC) function as pacemakers in gut motility and may play a role in the pathophysiology of the disease.

Methods: The ICC were examined by immunohistochemical staining with anti-c-kit antibody in the bowel walls of 6 neonates who had meconium obstruction without cystic fibrosis, and the results were compared with specimens from normal neonates (n = 2).

Results: Six patients underwent ileostomy between 2 and 15 days after birth, and 5 of them presented with microcolon. Ganglion cells were present in the ileum and colon. Whereas ICC were evenly distributed in the control specimens, they were not seen at the time of ileostomy in the colons of 2

patients, and the other 4 showed scanty distribution in muscle layers. However, ileum showed normal distribution of ICC in all patients. The ileostomies were closed between 39 and 104 days of age, and the ICC distribution was changed to a normal pattern in the colons of all 6 patients. Their bowel movements were restored to normal after closure.

Conclusion: The findings of this study suggest that delayed maturity of ICC may be a cause of meconium obstruction without cystic fibrosis.

J Pediatr Surg 37:1758-1761. Copyright 2002, Elsevier Science (USA). All rights reserved.

INDEX WORDS: Interstitial cells of Cajal, meconium ileus, motility disorder.

MECONIUM ILEUS is expressed mainly as a clinical manifestation of cystic fibrosis in the white population,^{1,2} however, a case of meconium ileus caused by cystic fibrosis has not been reported in Korea. Although meconium obstructions not related to cystic fibrosis were seen in Korean neonates, the etiology and the pathogenesis of the disease has not been elucidated.

Since the spindle-shaped interstitial cells of Cajal (ICC) were found by Cajal about one hundred years ago,³ numerous publications have contributed to find their origin and function. However, recent research from 1982⁴ found that ICC played a role of pacemaker in gut motility and the proto-oncogene *c-kit* was critical in the development of ICC.⁵⁻⁷ After Maeda et al⁶ blocked bowel function using the *c-kit* antagonist and found that the number of *c-kit* gene product-positive (*c-kit*⁺) cells decreased in the paralytic bowel, many studies using *c-kit* antibody have been undertaken to find the etiology of motility disorders.

When a neonate has evidence of intestinal obstruction without an apparent cause, one should consider the possibility of motility disorder secondary to pacemaker deficiency. In this study, we tried to determine the role of ICC in meconium obstruction by comparing the distribution of ICC in ileum and colon specimens obtained at the time of primary ileostomy and secondary ileostomy repair.

MATERIALS AND METHODS

From 1998 to 2001 we performed diverting ileostomy in 6 neonates because of meconium obstruction, none of whom had evidence of cystic fibrosis in other organs. The specimens obtained at the time of initial surgery included the proximal and distal ileum of obstruction site (n = 12) and colon (n = 6). Tissue samples at the time of ileostomy closure were obtained from resected ileum (n = 6), extraluminal biopsy of ascending colon (n = 5), and appendix by incidental appendectomy (n = 1). Control specimens were obtained from ileum or colon of 2 neonates who underwent massive bowel resection for midgut volvulus or who underwent colostomy for imperforate anus.

The *c-kit* immunohistochemical staining was performed as follows. Five-micrometer-thick slices of paraffin blocks were treated twice in xylene for 10 minutes each to remove paraffin, hydrated with alcohol, and washed with glucose solution. The tissue samples on the slide were placed in citric buffer at pH 6.0 and then placed in a pressure container. They were treated with microwave 3 times for 5 minutes each and placed in TRIS buffer for 5 minutes. After removing endogenous peroxidase by placing the tissue sample in 3% hydrogen peroxide diluted in methanol for 10 minutes, anti-rabbit polyclonal antibody (DAKO, Kyoto, Japan) was used as the primary antibody. Immunohistochemical staining was performed according to the standard peroxidase-labeled avidin-biotin complex method after incubating at 4°C for 12 hours. Counterstaining was done using hematoxylin.

The final evaluation was done by a single pathologist who had no clinical information, and the results were compared with that of the

From the Division of Pediatric Surgery and the Department of Pathology, Yonsei University Wonju College of Medicine, Wonju, Korea.

Presented at the 35th Annual Meeting of the Pacific Association of Pediatric Surgeons, La Jolla, California, May 12-16, 2002.

Address reprint requests to Soo-Young Yoo, MD, Pediatric Surgery, Yonsei University Wonju College of Medicine, 162 Ilsandong, Wonju 220-701, Korea (South).

Copyright 2002, Elsevier Science (USA). All rights reserved.

0022-3468/02/3712-0029\$35.00/0

doi:10.1053/jpsu.2002.36715

Table 1. Case Summary

Case	Sex	Contrast Study	Age (d)		Distribution of <i>c-kit</i> -Positive Cells			
			Ileostomy	Ileostomy Closure	Ileostomy		Ileostomy Closure	
					Ileum	Colon	Ileum	Colon
1	F	Microcolon	3	89	+	—	+	+
2	M	No microcolon	2	104	+	↓	+	+
3	F	Microcolon	15	91	+	↓	+	+
4	F	Microcolon	13	86	+	↓	+	+
5	M	Microcolon	8	58	+	↓	+	+
6	F	Microcolon	2	39	+	—	+	+

control group. The staining was determined as normal when red color was stained evenly around the myenteric plexus and throughout the interstitial space of inner circular muscle and outer longitudinal muscle layers. *c-kit* negativity or decrease was found when no red color staining appeared at all, or staining was done sporadically around some nerve plexus or muscle layer.

RESULTS

Multiple fluid-filled loops were detected prenatally in 5 patients by ultrasonographic examinations. Five of 6 were born between 38 weeks' and 41 weeks' gestation, weighing more than 3,000 g, whereas the sixth baby was born at 34 weeks' gestation weighing 2,150 g. Two patients were siblings. All 6 patients showed delayed meconium passage for more than 48 hours after birth together with abdominal distension, and 5 of them showed microcolon on contrast study (Table 1). Three patients underwent ileostomy at 2 to 3 days of age and laparotomy was delayed to 8 to 15 days after birth in the other 3 cases because we hoped for restoration of their bowel motility with gastrografin enemas. Initial operative findings of 4 cases showed typical meconium ileus in which the terminal ileum was filled with sticky meconium. The presence of ganglion cells was confirmed by frozen section biopsy of the specimens. The first 4 cases underwent double-barrel ileostomy, and the last 2 cases underwent distal ileostomy with end-to-side anastomosis. Distal bowel irrigation was done once a week in 6 patients after ileostomy, and ileostomy repair was accomplished between 39 and 104 days after confirming the excretion of contrast material within 24 hours after contrast study. All 6 cases showed normal bowel function after closure.

Compared with the control group, the *c-kit*-positive cells showed similar distribution in the ileum; however, almost no *c-kit*-positive cells was observed in the colon in 2 patients at the time of ileostomy (Fig 1A), and the other 4 patients showed scanty distribution in their colons (Fig 1B). The distribution of *c-kit*-positive cells changed from negative to positive, or increased significantly in all 6 cases at the time of ileostomy closure (Fig 1C).

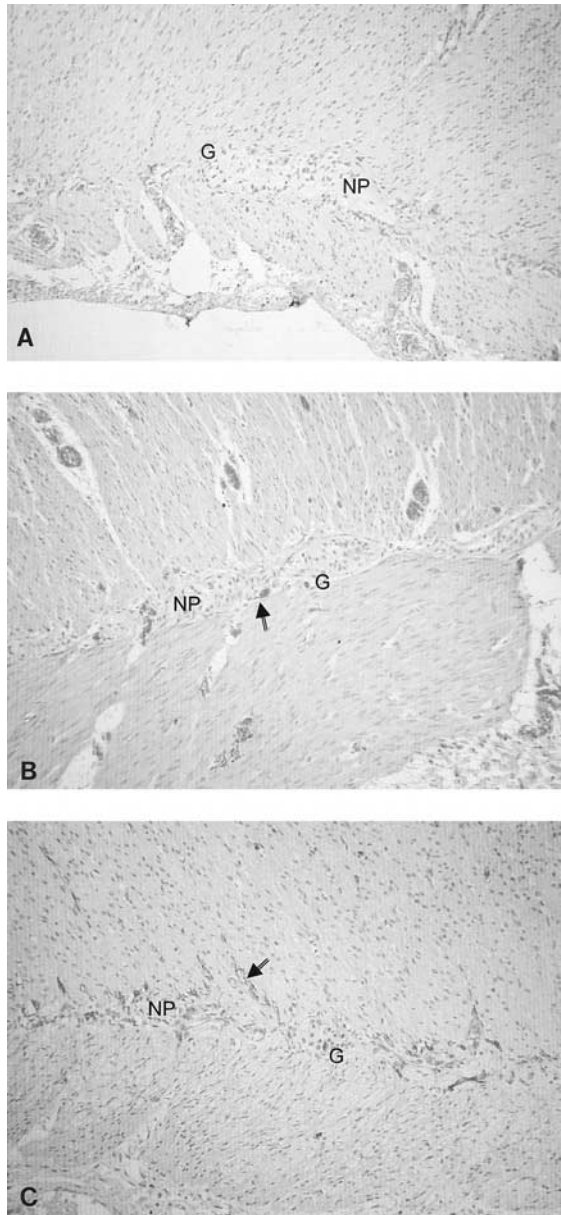
DISCUSSION

Pediatric surgeons usually suspect Hirschsprung's disease, meconium ileus, or intestinal atresia when abdominal distension and no or delayed bowel movement is present for more than 48 hours after birth. The possibility of meconium ileus is considered in Western countries when multiple air-fluid levels and calcification are shown on simple abdominal x-ray films and a microcolon on a contrast study. However, in Korea, pediatric surgeons initially would suspect intestinal atresia or total colonic aganglionosis when no abdominal calcification is present because of the rarity of cystic fibrosis in this country. Therefore, if there were clear findings of intestinal obstruction and microcolon on x-ray in Korea, the diagnosis usually was made at operation without preoperative rectal biopsy.

Meconium ileus-like condition without evidence of cystic fibrosis in other organs has been reported by Chinese⁸ and Japanese surgeons.⁹ Immaturity of the ganglia was suggested as the etiologic factor of meconium ileus in the Japanese report. Kenny et al¹⁰ also reported cases similar to ours and suggested delayed maturity of ICC as a cause of neonatal intestinal pseudo-obstruction for the first time.

Although it has been more than 100 years since the discovery of ICC, not much is known of their developmental origin. It has been suggested that ICC and smooth muscle cells both originated from mesenchymal precursor cells, unlike ganglion cells which arise from neural crest.^{11,12} Kenny et al¹³ studied that development of ICC in the human gastrointestinal tract from fetuses of 9 weeks' gestation and found that ICC were present from an early stage in human gut development, and ICC networks continued to develop postnatally.

Recent studies have found that ICC as a source of slow electrical activity mediated neural signals between enteric nerve and muscles^{14,15} and that various motility disorders such as Hirschsprung's and allied Hirschsprung's disease,¹⁶⁻¹⁸ transient neonatal pseudo-obstruction,¹⁰ hypomotility associated with anorectal malformations,¹⁹ chronic idiopathic intestinal pseudo-obstruction,²⁰



slow-transit constipation,²¹ neuronal intestinal dysplasia,²² and Crohn's disease²³ were associated with ICC abnormality. Nemeth et al²⁴ reported a possible relationship between impairment of intercellular communication and motility dysfunction in Hirschsprung's disease based on the finding that the immunoreactivity of the gap junction protein, Connexin 43, between *c-kit*-positive cells and smooth muscle cells was not shown in the aganglionic bowel.

Our cases were unique in that the obstruction owing to meconium was all located in the terminal ileum, but ICC distribution was normal even in the obstructed distal ileum, whereas it was negative or decreased in the colon. We found that the time required to recover normal bowel function varied according to each patient possibly because the degree for ICC maturation varied among the patients. Deciding whether to proceed with surgery in our 6 patients with meconium obstruction was difficult because we were not sure whether the obstructive symptoms resolve with rectal enemas alone.

As shown in our study results, the possibility of ICC immaturity needs to be considered when the symptoms of meconium obstruction are present in the terminal ileum in neonates who have no definite causative disease of obstruction. Furthermore, we need to accumulate more experience for appropriate treatment of these patients.

Fig 1. Microscopic findings of *c-kit* immunohistochemical staining (Original magnification $\times 200$). (A) Case 1 (age, 2 days): the ascending colon shows no immunopositive cells at the time of ileostomy. Normal ganglion cells (G) are present in the nerve plexus (NP). (B) Case 4 (age, 8 days): the colon shows a scanty distribution of *c-kit*-positive cells (arrow) only around the myenteric plexus. (C) Case 4 (age, 86 days): The *c-kit*-positive cells (arrow) in the colon appear to be around the myenteric plexus and intermuscular space at the time of ileostomy closure.

REFERENCES

1. Fakhoury K, Durie PR, Levison H, et al: Meconium ileus in the absence of cystic fibrosis. *Arch Dis Child* 67:1204-1206, 1992
2. Mushtaq I, Wright VM, Drake DP, et al: Meconium ileus secondary to cystic fibrosis. The East London experience. *Pediatr Surg Int* 13:365-369, 1998
3. Thuneberg L: One hundred years of interstitial cells of Cajal. *Microsc Res Tech* 47:223-238, 1999
4. Thuneberg L, Rumessen, JJ, Mikelson HB: Interstitial cells of Cajal—An intestinal impulse generation and conduction system? *Scand J Gastroenterol Suppl* 71:143-144, 1982
5. Orr-Urtregar A, Avivi A, Zimmer Y, et al: Developmental expression of *c-kit*, a protooncogene by the W locus. *Development* 109:911-923, 1990
6. Maeda H, Yamagata A, Nishikawa S, et al: Requirement of *c-kit* for development of intestinal pacemaker system. *Development* 116: 369-375, 1992
7. Huizinga JD, Thuneberg L, Kluppel M, et al: W/*kit* gene required for interstitial cells of Cajal and for intestinal pacemaker activity. *Nature* 373:347-349, 1995
8. Chang PY, Huang FY, Yeh ML, et al: Meconium ileus-like condition in Chinese neonates. *J Pediatr Surg* 27:1217-1219, 1992
9. Toyosaka A, Tomimoto Y, Nose K, et al: Immaturity of the myenteric plexus is the aetiology of meconium ileus without mucoviscidosis: A histopathologic study. *Clin Auton Res* 4:175-184, 1994
10. Kenny SE, Vanderwinden JM, Rintala RJ, et al: Delayed maturation of the interstitial cells of Cajal: A new diagnosis for transient neonatal pseudoobstruction. Report of two cases. *J Pediatr Surg* 33:94-98, 1998
11. Young HM: Embryological origin of interstitial cells of Cajal. *Microsc Res Tech* 47:303-308, 1999
12. Kluppel M, Huizinga JD, Malysz J, et al: Developmental origin

and Kit-dependent development of the interstitial cells of Cajal in the mammalian small intestine. *Dev Dyn* 211:60-71, 1998

13. Kenny SE, Connell G, Woodward MN, et al: Ontogeny of interstitial cells of Cajal in the human intestine. *J Pediatr Surg* 34:1241-1247, 1999

14. Hanani M, Freund HR: Interstitial cells of Cajal—Their role in pacing and signal transmission in the digestive systems. *Acta Physiol Scand* 170:177-190, 2000

15. Yamazawa T, Lino M: Simultaneous imaging of Ca (2+) signals in interstitial cells of Cajal and longitudinal smooth muscle cells during rhythmic activity in mouse ileum. *J Physiol* 538:823-835, 2002

16. Vanderwinden JM, Rumessen JJ, Liu H, et al: Interstitial cells of Cajal in human colon and in Hirschsprung's disease. *Gastroenterology* 111:901-910, 1996

17. Horisawa M, Watanabe Y, Torihashi S: Distribution of c-Kit immunopositive cells in normal human colon and in Hirschsprung's disease. *J Pediatr Surg* 33:1209-1214, 1999

18. Yamataka A, Ohshiro K, Kobayashi H, et al: Intestinal pacemaker C-KIT+ cells and synapses in allied Hirschsprung's disease. *J Pediatr Surg* 32:1069-1074, 1997

19. Kenny SE, Connell MG, Rintalla RJ, et al: Abnormal colonic interstitial cells of Cajal in children with anorectal malformations. *J Pediatr Surg* 33:130-132, 1998

20. Yamataka A, Ohshiro K, Kobayashi H, et al: Abnormal distribution of intestinal pacemaker (C-KIT-positive) cells in an infant with chronic idiopathic intestinal pseudoobstruction. *J Pediatr Surg* 33:859-862, 1998

21. He CL, Burgart L, Wang L, et al: Decreased interstitial cell of Cajal volume in patients with slow-transit constipation. *Gastroenterology* 118:14-21, 2000

22. Jeng TM, Mao TL, Hsu WM, et al: Congenital interstitial cell of cajal hyperplasia with neuronal intestinal dysplasia. *Am J Surg Pathol* 24:1568-1572, 2000

23. Porcher C, Baldo M, Henry M, et al: Deficiency of interstitial cells of Cajal in the small intestine of patients with Crohn's disease. *Am J Gastroenterol* 97:118-125, 2002

24. Nemeth L, Maddur S, Puri P: Immunolocalization of the gap junction protein Connexin 43 in the interstitial cells of Cajal in the normal and Hirschsprung's disease bowel. *J Pediatr Surg* 35:823-828, 2000